

Received: 2013.08.29
Accepted: 2013.10.09
Published: 2014.03.20

Safety and efficacy of a novel disposable circumcision device: A pilot randomized controlled clinical trial at 2 centers

Authors' Contribution:
Study Design A
Data Collection B
Statistical Analysis C
Data Interpretation D
Manuscript Preparation E
Literature Search F
Funds Collection G

ABDE 1 **Jingen Wang**
BG 2 **Yongfei Zhou**
B 3 **Shuxia Xia**
BF 1 **Zunwei Zhu**
BF 1 **Linghua Jia**
B 2 **Yong Liu**
ACDE 4 **Min Jiang**

1 Department of Urology, Jiangxi Provincial People's Hospital, Nanchang, China
2 Yongfeng Traditional Chinese Medicine Hospital, Yongfeng, China
3 Department of Urology, Affiliated Hospital of Jiangxi College of Traditional Chinese Medicine, Nanchang, China
4 Institution of Clinical Trial, Jiangxi Provincial People's Hospital, Nanchang, China

Corresponding Author: Min Jiang, e-mail: jmxc@163.com
Source of support: Departmental sources

Background: We evaluated the safety and efficacy of a novel disposable male circumcision (MC) device developed by Jiangxi-Yuansheng-Langhe Medical Instrument Co., Ltd.





Material/Methods: Adult male patients ($n=120$; mean age, 26.6 years) with redundant foreskin and/or phimosis were included in a randomized, multicenter pilot clinical trial from October 2011 to February 2012. Patients were divided into 2 groups and subjected to MC with a novel disposable device (Device Group) ($n=60$) or to conventional dissection technique (CDT) (Control Group) ($n=60$). Intraoperative bleeding, surgery duration, pain, healing, and satisfaction with penis appearance were assessed. Adverse events (AEs) were noted.

Results: Intraoperative bleeding volume [3.5 ± 2.7 (15–35) ml vs. 13.1 ± 6.1 (4–25) ml] and mean surgical time [7.6 ± 4.5 (2–23) min vs. 23.6 ± 4.4 (15–35) min] in the Device Group were significantly less than in the Control Group ($P<0.01$). No AEs were observed in either group. There were no significant differences in postoperative pain, healing, or satisfaction with penis appearance between groups ($P>0.05$).

Conclusions: This novel disposable circumcision device produced satisfactory preliminary adult MC results compared with CDT treatments. This device may be broadly used in men, such as those with phimosis, who are ineligible for CDT.

Keywords: **Male Circumcision • Circumcision Device • Redundant Foreskin**

Full-text PDF: <http://www.medscimonit.com/download/index/idArt/889722>

 3289  3  3  16

Background

The average male circumcision (MC) rate worldwide among non-Muslims is estimated to be 30–34%, and MC is increasingly common in West Africa, the United States, areas of central and Eastern Africa, and the Republic of Korea [1,2]. In China, however, less than 5% of males undergo MC, and the majority of these cases are related to alleviation of late-stage complications, such as tightened foreskin that prevents full exposure of the glans penis (phimosis) [3]. The acceptability of MC has recently increased in China, with 44.6% of patients accepting the procedure [4], but remains relatively low compared with other populations [5]. MC may reduce sexually transmitted diseases and cancer susceptibility and improve general health, but patients and practitioners are often concerned with rare complications, such as excessive intra- and postoperative wound bleeding, hematoma, infection, secondary phimosis, epidermal inclusion cysts, and urinary dysfunction [6]. Thus, there is a need for more effective and safer methods for MC.

Primary MC is achieved by removing the preputial tissue without damaging the glans penis and frenulum, generally by procedures such as the dorsal slit, squeeze, sleeve resection, guillotine procedures, and conventional dissection technique (CDT) [7]. Recently, minimally invasive surgical devices, such as disposable clamps, have been used to reduce complications, bleeding, and surgical times [8]. Several proprietary devices have been designed to improve MC surgery [9].

The aim of the present study was to evaluate the safety and efficacy of a novel disposable device for MC. A multi-center pilot clinical trial was conducted at 2 Chinese hospitals to compare intra- and postoperative outcomes of MC using this device with CDT.

Material and Methods

Clinical data

A total of 120 patients with redundant foreskin and/or phimosis were included in this randomized, multicenter pilot clinical trial from October 20, 2011 to February 12, 2012. Patients were randomly divided into 2 groups using a computerized random table method generated by SAS 8.0 (SAS, Cary, NC) and treated with circumcision surgery using a novel disposable device (Yuanshenglanghe Biological Hi-tech Co. Ltd., Jiangxi, China) (Device Group) ($n=60$) or CDT surgery (Shanghai Medical Instruments Co. Ltd., Shanghai, China) (Control Group) ($n=60$). Age, height, weight, body temperature, resting pulse and respiration, and blood pressure were recorded for all participants prior to surgery (Table 1). All procedures were carried out at the Jiangxi Province People's Hospital ($n=72$) or at the

Jiangxi University of Traditional Chinese Medicine ($n=48$). This study was approved by the Medical Ethics Committee of the Jiangxi Province People's Hospital (approval No. 2011-clinical inspection 20) with the authorization of the Medical Ethics Committee of the Jiangxi University of Traditional Chinese Medicine. Informed consent was signed by all enrolled patients. All clinical trial procedures were conducted according to established standards and protocols, and both facilities met the standards of the State Food and Drug Administration (SFDA) of China.

Patients

Inclusion criteria were: (1) males older than 16 years; (2) diagnosed with redundant prepuce (glans penis covered completely or partially by prepuce under the relaxed condition, and a glans penis that is uncovered with the coronary sulcus exposed by force) or phimosis (narrowed ostium praeputiale and inability to expose the glans penis by force or the prepuce cannot return to its original position after forced upturning) [3]; and (3) willing to sign informed consent for study participation. Exclusion criteria were: (1) penis size or shape incompatible with the tested device (non-erect size other than 69–88 mm in circumference or 22–28 mm in diameter), as determined by the use of a special measuring tape for penis circumference at the coronal sulcus; (2) malformations of the glans penis or prepuce, including wide-range adhesion between glans penis and prepuce; (3) infection and edema of the glans penis or prepuce; (4) suspected penis carcinoma; (5) systemic diseases, such as bleeding tendency, hypoproteinemia, or serious cardiovascular disease; (6) other surgical contradictions; (7) participation in another clinical trial of medical devices or drugs within the past 30 days; and (8) refusal to comply with study protocols. All patients were subjected to routine preoperative testing, including vital signs, routine blood examination, blood coagulation tests, and electrocardiogram (ECG), resulting in a complete current medical record for each patient.

Male circumcision device

Novel device license

A novel disposable circumcision device developed by Jiangxi-Yuansheng-Langhe Medical Instrument Co., Ltd. (type No. 26, batch production No. 20110501) and approved by the Food and Drug Administration of Jiangxi Province was used in the Device Group. The device's performance and physical, chemical, and biological properties qualified for passing inspection (report No: YQZC20110168). One patent for the device has been granted (patent No: ZL 200920241688.7) and clinical product registration has been filed with the State Food and Drug Administration (SFDA) (registration No. 2012–2660084).

Table 1. Demographic and clinical characteristics.

	Device group		Control group	
Demographics [#]				
Age (years)	26.2±7.6	(18–48)	26.9±10.8	(17–67)
Height (cm)	171.3±5.0	(158–185)	171.2±5.7	(158–182)
Body weight (kg)	64.3±8.8	(45–86)	64.4±8.3	(47–85)
Clinical baseline [#]				
Temperature (°C)	36.41±0.26	(36.0–37.1)	36.45±0.27	(36.0–37.1)
Pulse (beats/min)	75.5±7.8	(51–100)	77.8±6.9	(67–94)
Respiration (breaths/min)	20.1±1.5	(14–29)	19.9±0.7	(18–22)
SBP (mmHg)	116.3±10.2	(95–146)	117.4±12.0	(95–148)
DBP (mmHg)	72.0±8.8	(59–96)	71.3±8.5	(60–94)
Preoperative condition				
Redundant foreskin	43/60		44/60	
Phimosis	17/60		16/60	
Clinical examinations				
Physical examination*	1/59		0/60	
Allergy history**	0/60		1/59	
Other complications**	1/59		1/59	
Routine blood tests*				
WBC	5/55		5/55	
RBC	9/51		7/53	
HgB	3/57		6/54	
Platelets	2/58		1/59	
Coagulation function*				
PT	6/54		4/56	
PT-INR	4/56		3/57	
aPTT	0/60		1/59	
TT	7/53		10/50	
Electrocardiogram*	9/51		8/51	

P>0.05 for all data; * Measured as (abnormal/normal); ** Measured as (yes/no); # Data presented as mean ±SD (Range). SBP – systolic blood pressure; DBP – diastolic blood pressure; WBC – white blood cell count; RBC – red blood cell count; HgB – hemoglobin; PT – prothrombin time; INR – international normalized ratio; aPTT – activated partial thromboplastin time; TT – thrombin time.

Description of the device

Device weight ranges between 100 and 300 g and is composed of stainless steel and plastic elements. The scalpel is made of No. 304 stainless steel according to the Chinese standard

GB3280-92, and the other accessories are made of PC and ABS plastics. Five sizes of the device are available to fit various penis sizes. Device type is specified according to the diameter of the ring-shaped scalpel, divided into the 5 sizes by type (36, 30, 26, 18, and 12), with diameters of the ring-shaped scalpel

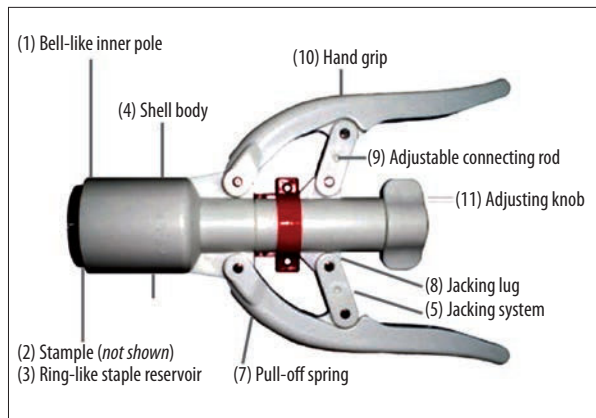


Figure 1. Image of the device with labeled parts.

of 36 mm, 30 mm, 26 mm, 18 mm, and 12 mm, respectively. The device consists of an inner rod (glans penis seat cover) and an outer pole, including the following items: (1) bell-like inner pole; (2) staple; (3) ring-like staple reservoir; (4) shell body; (5) jacking system; (6) ring-like scalpel; (7) pull-off spring; (8) jacking lug; (9) adjustable connecting rod; (10) hand grip; and (11) adjusting knob (Figure 1). A control handle is fixed on the outside of the outer pole and a connecting interface links with the inner rod from the inside. The disposable ring-shaped scalpel and staples are assembled in the outer pole.

Device packaging and sterilization

The device is individually packaged in a hermetically sealed foil-covered paper bag and sterilized by γ -ray radiation by the manufacturer. The device is designed for one-time use and is safe for routine disposal of biologically hazardous products for medical use.

Surgical treatments

Anesthesia

For all patients, local anesthesia was performed with preoperative 1% lidocaine hydrochloride injection (10–20 ml).

Conventional dissection technique (CDT) treatment

Two experienced surgeons from the Department of Urology of each facility performed CDT on each Control Group patient using the conventional sleeve technique, as previously described [11]. In the present study, the conventional approach involved resection of the redundant foreskin using scalpel or scissors. The inner mucosal layer was trimmed to 3 mm above the corona region. After meticulous hemostasis obtained by unipolar electrocautery (power maximum of 25 W), edges of the skin were approximated using absorbable sutures (Shanghai Medical Instruments Co., Ltd., Shanghai, China).

Novel disposable device treatment

Two experienced surgeons from the Department of Urology of each facility performed MC using a novel disposable device on each Device Group patient. For consistency, devices from a single manufacturing batch were used for all procedures. Patients were subjected to foreskin fixation with 1 end of the inner rod of the device, while the other end was used as a control knob to immobilize the outer pole. The surgical procedure was initiated by placing the inner rod on the glans penis, followed by lifting the foreskin with vascular clamps and placing it on the outside of the inner rod (Figure 2A). The foreskin was fixed onto the outer pole (Figure 2B), and the control knob was inserted into the free end of the outer pole and fixed with the inner rod. The control handle was then adjusted to the appropriate position (Figure 2C). The operator stabilized the outer pole with one hand, and clasped the control levers with the other hand, resulting in removal of the redundant foreskin while the incision was simultaneously closed with staples (Figure 2D). The control knob was rotated counter-clockwise to remove the inner rod and the outer pole, and the surgical incision was bandaged (Figure 2E).

Criteria for operative device success and failure

At the time of surgery, device success was defined as the complete removal of redundant foreskin, glans penis exposure, and wound closure without active bleeding. During surgery using the device, manipulations were immediately ceased if abnormal reactions or complications due to device use were observed or if the patient poorly tolerated use of the device for any reason. In instances where it was impossible to complete the surgery using the device, CDT was performed (Device-CDT Crossover Patient Group) and the operation was reported as a device failure.

Post-surgical treatment

Postoperative oral antibiotics (0.5 g cephalosporin, TID) were administered for 2 days following surgery and antipyretic and analgesic drugs (250 mg acetaminophen, per day) were administered for postoperative pain. Patients were instructed to rest, avoid intensive physical activities that could result in incisional hematoma formation, and maintain good hygiene.

Assessments and follow-up

Intra-operative assessment

Intraoperative vital signs, bleeding volume (estimated from blood-soaked gauze), hemostasis, and surgical duration (not including anesthesia administration, which was administered consistently in patients treated with the device or CDT) were recorded for each patient. A piece of 8-fold (7×8 cm) gauze can

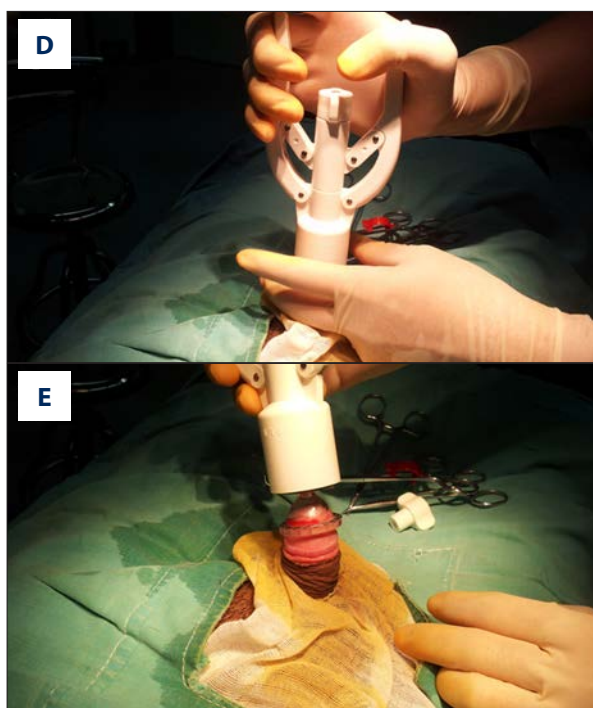
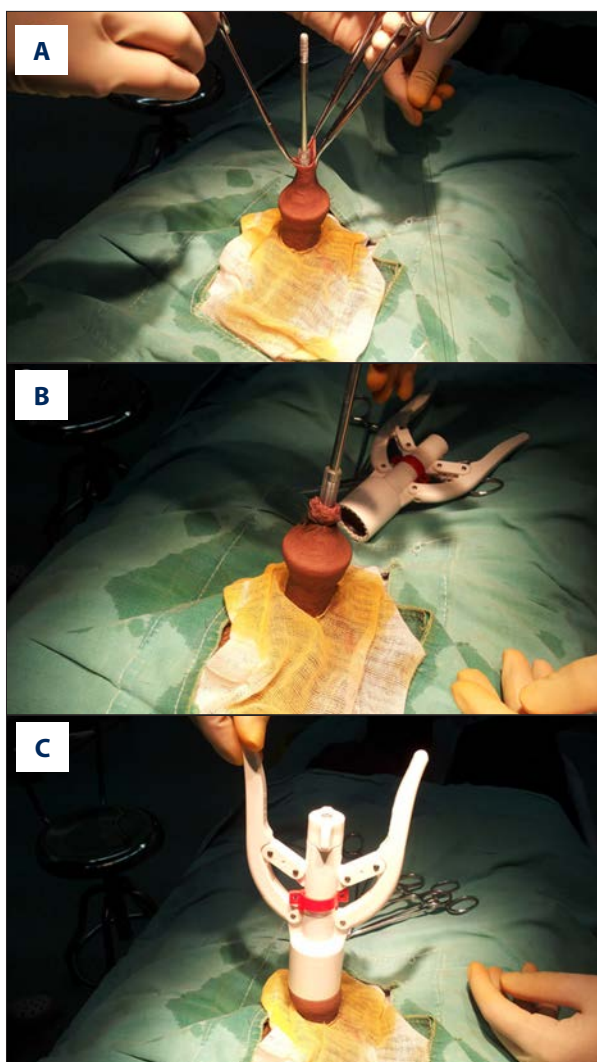


Figure 2. Surgical procedure using the novel, disposable circumcision device. (A) Placement of the inner rod on the glans penis and lifting of foreskin with vascular clamps; (B) fixation of the foreskin onto the outer pole; (C) control knob insertion into the free end of the outer pole and inner rod fixation with proper positioning of the control handle; (D) stabilization of the outer pole (left hand) and adjustment of control knobs (right hand), resulting in redundant foreskin removal and staple closure simultaneously; and (E) counter-clockwise control knob rotation to remove the inner rod and the outer pole.

absorb approximately 3 mL blood when completed saturated. Intra-operative safety was evaluated by recording intraoperative accidents due to mechanical problems associated with the device and occurrence of adverse events (AEs) such as post-operative hemorrhage and incision dehiscence.

Post-operative assessment

Follow-up was conducted on days 1, 3, 7, and 14 following surgery. Each patient underwent follow-up examinations in-clinic, where they completed a written assessment of surgery. Post-operative safety was assessed by examining postoperative pain, incisional healing time, and occurrence of AEs such as infection. Pain was reported as minor (no or slight pain), moderate (tolerable pain), or severe (intolerable pain requiring medication or intervention with acetaminophen, as previously described) on days 1, 3, 7, and 14. Healing was reported as either ‘not healed’ (readily apparent visible areas of open wound) or ‘acceptable healing’ (surgical incision wound completely covered

by epithelium with no apparent mismatch of the skin, break, or scabbing) on days 7 and 14. Patient satisfaction with penile appearance was assessed as satisfaction with appropriate foreskin removal, proper chalaza (frenulum of foreskin) length, neatness of incision edge, and healing on day 14 according to the scale: poor (unsatisfied), moderate (satisfied), satisfied (fully satisfied).

Statistical analysis

According to non-inferiority trial estimates, 50 subjects in each group were required to achieve an average surgical success rate of 97% with a 10% non-inferiority boundary, as used in the present study. Categorical data are presented as frequencies and ratios, and continuous variables are presented as mean ± standard deviation, maximum values, and minimum values. Chi-square test or Fisher’s exact test were used for between-groups comparisons, as appropriate. McNemar test were used for comparisons within groups, and *t* tests were used to compare normally distributed data. Data with non-normal

Supplementary Table 1. Postsurgical vital signs for the two treatment groups.

Group		Body temperature (°C)*	Pulse rate*	Respiratory rate*	SBP*	DBP*
Pre-surgical day 0	Device	36.41±0.26 (36.0–37.1)	75.5±7.8 (51–100)	20.1±1.5 (14–29)	116.3±10.2 (95–146)	72.0±8.8 (59–96)
	Control	36.45±0.27 (36.0–37.1)	77.8±6.9 (67–94)	19.9±0.7 (18–22)	117.4±12.0 (95–148)	71.3±8.5 (60–94)
Post-surgical day 1	Device	36.47±0.26 (36.0–37.0)	76.8±8.5 (53–107)	19.8±1.0 (16–22)	116.8±10.4 (95–135)	72.2±8.4 (59–100)
	Control	36.49±0.24 (36.0–37.0)	78.1±7.6 (65–105)	19.8±0.8 (16–22)	117.2±10.7 (95–139)	72.3±8.3 (60–95)
Post-surgical day 3	Device	36.48±0.23 (36.1–37.1)	76.5±8.2 (51–106)	19.6±0.5 (18–21)	116.4±9.7 (95–137)	72.2±7.1 (60–96)
	Control	36.50±0.19 (36.0–37.0)	77.8±6.7 (65–106)	19.6±0.6 (18–21)	116.0±10.2 (95–135)	71.7±7.6 (58–90)
Post-surgical day 7	Device	36.49±0.24 (36.1–37.1)	75.9±7.9 (57–98)	19.9±0.5 (18–21)	117.7±10.9 (93–150)	73.5±9.6 (59–110)
	Control	36.50±0.23 (36.1–37.0)	77.3±6.3 (65–90)	20.0±1.2 (18–28)	116.5±10.9 (95–140)	71.8±8.4 (56–88)
Post-surgical day 14	Device	36.46±0.23 (36.0–37.1)	75.4±6.6 (58–98)	19.9±0.6 (18–21)	116.3±10.2 (95–131)	72.4±6.7 (60–87)
	Control	36.48±0.25 (36.1–37.1)	77.5±5.3 (65–89)	19.8±0.8 (16–21)	115.7±10.6 (95–140)	71.6±7.7 (60–88)
Comparison between two time points		<i>P</i> >0.05	<i>P</i> >0.05	<i>P</i> >0.05	<i>P</i> >0.05	<i>P</i> >0.05
Intergroup comparison		<i>P</i> >0.05	<i>P</i> >0.05	<i>P</i> >0.05	<i>P</i> >0.05	<i>P</i> >0.05

* Data was presented as mean ±SD (Range). SBP – systolic blood pressure; DBP – diastolic blood pressure.

distributions were compared with the Wilcoxon rank sum test. SPSS 12.0 (SPSS Inc, Chicago, IL) was used for all statistical analyses. *P* values <0.05 were considered statistically significant, and the expected confidence interval (CI) was 90%.

Results

Clinical characteristics

After exclusion of 15 patients for failure to meet penis size requirements, 120 patients were included in the study. No significant differences in age (mean 26.6 years, range 17–67 years), height, or weight were observed between the groups (*P*>0.05). In addition, no significant changes in clinical baseline parameters, clinical examination results, routine blood test results, or ECG findings were observed between the Device and Control Groups (*P*>0.05) (Table 1). In the Device Group, phimosis was observed in 17 patients and prepuce (redundant foreskin) was observed in 43 patients, with 2 exclusions. In the Control Group, phimosis was observed in 16 patients and prepuce (redundant foreskin) was observed in 44 patients. Notably, the majority of affected patients were young adults, with a mean age of 26.2±7.6

(18–48) years and 26.9±10.8 (17–67) years in the Device and Control Groups, respectively. No significant variations of body temperature, pulse, respiration, systolic blood pressure, and diastolic blood pressure were observed between the Device and Control Groups at presurgical examinations or at follow-up day 1, 3, 7, or 15 (*P*>0.05) (Supplementary Table 1). Notably, similar results were found at both study centers (data not shown).

Intraoperative time and bleeding results

Significantly lower estimated intraoperative bleeding was observed in the Device Group (mean 3.5±2.7 ml, ranging 15–35 ml) compared with the Control Group (mean 13.1±6.1 ml, range 4–25 ml) (*P*<0.01), and no AEs due to postoperative bleeding or hematoma formation were reported in either group. Significantly different mean surgical times of 7.6±4.5 (2–23) min and 23.6±4.4 (15–35) min in the Device Group and the Control Group, respectively, were observed (*P*<0.01).

Surgical success rates and adverse events

Surgical success rates of 96.7% (58/60) and 100% 60/60 were observed in the Device Group and Control Group, respectively.

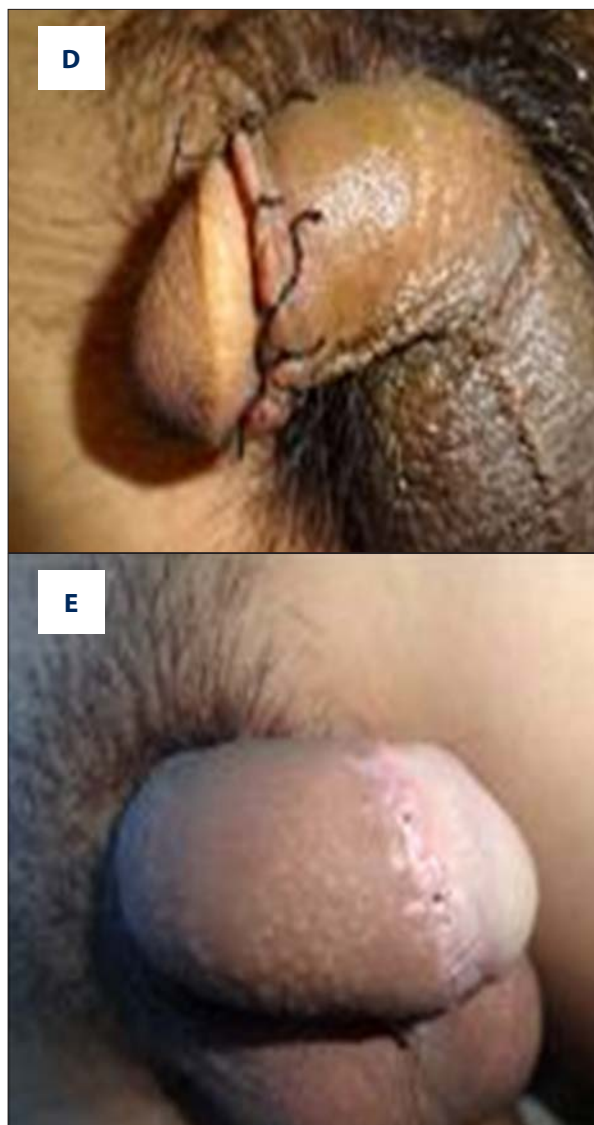
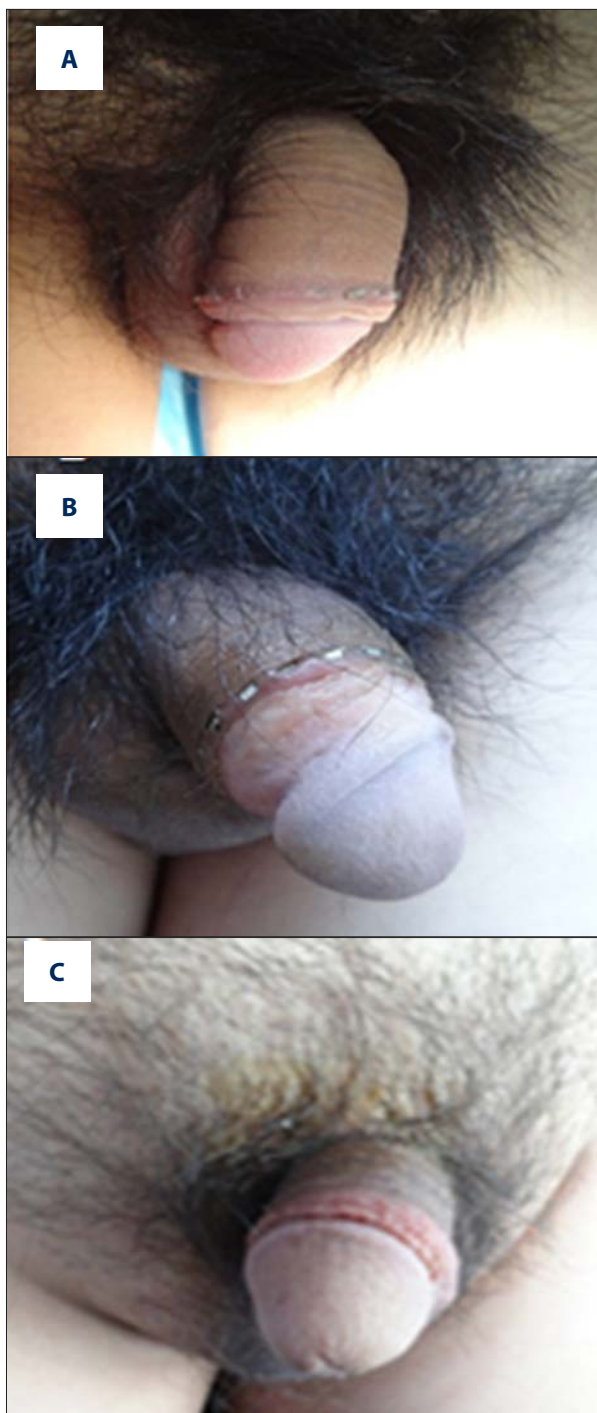


Figure 3. Wound healing following MC with the disposable circumcision device. (A) Wound after staple suture placement; (B) wound appearance after some staples were dislodged; (C) wound appearance after all staples spontaneously dislodged; (D) wound appearance with conventional sutures; and (E) wound appearance after suture removal.

Outcomes of surgical MC treatments

Notably, device-to-CDT crossover patients (ie, patients randomized to the Device Group but who required CDT) were not included in the analysis. CDT was used following device failure due to insufficient hemostasis ($n=1$) and mechanical failure of the device ($n=1$). Thus, 58 patients completed treatment in the Device Group. Notably, no device-related accidents causing patient injury, postsurgical wound bleeding, dehiscence, infection, or other AEs were observed in any group.

Sutures were manually removed 1 week postoperatively for all patients in the Control Group. Most staples used for incisional closure in the Device Group fell out spontaneously, demonstrating complete covering of the wound by epithelium (‘acceptable healing’) at the incision site. Furthermore, visual examination revealed smooth incision edges with neat suture scars in all cases. Wound healing and staple dislodging is shown in Figure 3A–3E. In the Device Group, only 9 patients required manual removal of staples covered by *de novo* tissues at follow-up day 14.

Table 2. Postoperative pain, wound healing, and satisfaction by day.

Postoperative day	Group (n)	Pain			Healing condition		Degree of satisfaction		
		Minor	Moderate	Severe	Not healed	Acceptable healing	Satisfied	Moderate	Poor
Day 1	Device (58)	53	4	1					
	Control (60)	54	6	0					
	P-value	P>0.05							
Day 3	Device (58)	55	3	0					
	Control (60)	53	7	0					
	P-value	P>0.05							
Day 7	Device (58)	55	3	0	9	49			
	Control (60)	60	0	0	7	53			
	P-value	P>0.05			P>0.05				
Day 14	Device (58)	58	0	0	0	58	56	2	0
	Control (60)	60	0	0	0	60	57	3	0
	P-value	P>0.05							

The majority of patients in both groups reported acceptable healing by day 7 (88%, 53/60 Control Group patients; 83%, 48/58 Device Group patients). By day 14, all patients reported complete covering of the wound by epithelium, consistent with the acceptable healing designation. By day 14, 55/58 (95%) Device Group patients and 57/60 (95%) Control Group patients reported full satisfaction with MC outcomes. Notably, only 2 (3%) and 3 (5%) patients of the Device Group and Control Group, respectively, reported moderate satisfaction. No patient reported poor satisfaction in any group. No significant differences were observed in any outcomes between the 2 groups.

No significant difference in postoperative pain, wound healing, or satisfaction were reported between the 2 groups for any day of follow-up ($P>0.05$) (Table 2).

Discussion

The present study demonstrates that MC using a novel, disposable device provided equivalent outcomes with current CDT treatment. Notably, MC using the device resulted in shorter surgical times and reduced bleeding compared with CDT treatment. Furthermore, these findings indicate that Device Group surgeries were much faster than CDT surgeries. These observations indicate that this novel disposable device may be a valid alternative treatment for adult MC.

MC has been widely used to limit the spread of sexually transmitted diseases such as HIV in Africa and Western countries [4,5]. It may also limit other reproductive tract diseases, including urinary infection and penile cancer [10,11]. Many adult patients, particularly in China where MC is less well-accepted, are concerned with the potential drawbacks of conventional circumcision [12], including repeat circumcision, surgical complications, impairment in sexual abilities, and cost [6]. Notably, the cost of the device studied is also expected to be relatively low, but it is not yet in commercial production. The recent development of minimally invasive and disposable instruments for circumcision has increased acceptability of MC by patients [6]. Thus, new devices that leverage these benefits are highly desirable.

Various non-disposable [13,14] and disposable [9,15] circumcision devices have been developed that effectively prevent intraoperative bleeding by clamping the superficial dorsal veins and vessels between an inner and outer ring prior to transection of the foreskin, allowing the foreskin to be removed surgically or by natural atrophy. As a result, these techniques produce very little bleeding and may limit infection, pain, and other risks associated with adult MC [9,13–15]. In comparison, the superficial dorsal vein of the penis is directly ligated during conventional MC surgery and hemostasis is achieved with sutures, causing a relatively large amount of intraoperative bleeding [7]. Although the disposable device used in the current trial has an inner rod and outer pole, instead of the inner and outer rings found in devices such as the PrePex [12], it functions in a manner similar to these devices. Thus, this device can prevent intraoperative

hemorrhage by physically occluding blood vessels between device rings. The present study provides preliminary indications that this device may provide superior results compared with CDT.

Use of most disposable devices requires no sutures. However, rings must be manually removed 5–7 days after surgery, increasing the risk of postoperative hemorrhage, which is reported to be approximately 0.6% of all treated patients [9]. Notably, the present device contains no rings, but instead fixes the foreskin in place with a ‘glans penis seat cover’ for removal by a ring-shaped scalpel followed by immediate fixation by stapling. Further study will be required to assess whether this device could potentially improve postoperative hemorrhage risks compared with other disposable devices. The present study demonstrated that these staples are usually spontaneously removed within 2 weeks following surgery.

Conventional circumcision requires subjective assessments by the operator, which are generally improved by experience and surgical skill, eventually resulting in optimal incision, intervention in the case of intraoperative hemostasis, and cosmetically acceptable wound closure [7]. In contrast, special skills and training are not required for optimal operation of the present disposable circumcision device. This greatly simplifies the procedure and significantly reduces surgical times compared with CDT treatment. While the current pilot study was not large enough to fully assess AEs with low occurrence rates, this treatment may be able to reduce penis injuries and postoperative complications such as infections [5,16]. Thus, in areas where medical resources are limited, such as rural and underdeveloped Chinese and African regions [5], this device may minimize patient risks.

Similar results were obtained at 2 independent Chinese facilities, indicating that different surgeons can perform the procedure

References:

1. Ben KL, Xu JC, Lu L et al: Male circumcision is an effective “surgical vaccine” for HIV prevention and reproductive health. *Zhonghua Nan Ke Xue*, 2009; 15: 395–402
2. UNAIDS/WHO: Progress in male circumcision scale-up: Country implementation and research update. Geneva: World Health Organisation, 2009
3. UNAIDS: Male circumcision: Global trends and determinants of prevalence, safety, and acceptability: Geneva: World Health Organisation, 2009
4. Yang X, Abdullah AS, Wei B et al: Factors influencing Chinese male’s willingness to undergo circumcision: a cross-sectional study in western China. *PLoS One*, 2012; 7: e30198
5. Herman-Roloff A, Otieno N, Agot K et al: Acceptability of medical male circumcision among uncircumcised men in Kenya one year after the launch of the national male circumcision program. *PLoS One*, 2011; 6: e19814
6. Krill AJ, Palmer LS, Palmer JS: Complications of circumcision. *ScientificWorldJournal*, 2011; 11: 2458–68
7. Basar H, Yilmaz E, Basar MM et al: Window technique on circumcision. *Int Urol Nephrol*, 2006; 38: 599–601
8. Schmitz RF, Schulpen TW, Redjopawiro MSet al: Religious circumcision under local anaesthesia with a new disposable clamp. *BJU Int*, 2001; 88: 581–85
9. Peng YF, Cheng Y, Wang GY et al: Clinical application of a new device for minimally invasive circumcision. *Asian J Androl*, 2008; 10: 447–54

successfully with minimal training. This study may also be limited by the lack of blinding. While further study will be required using larger and more diverse patient cohorts, this pilot study provides preliminary indications that this device is safe and effective for MC compared with CDT treatments. Studies with larger patient cohorts are still required, but we expect that complications and AEs will occur at very low rates, similar to those reported for other circumcision devices [6]. The present device is currently only available in a limited range of sizes, thus limiting its application in very young patients and patients with abnormal penis sizes. Therefore, accommodations for different penis sizes should be considered when the device goes into large-scale production.

Conclusions

The proposed novel device performed well in this preliminary study, thereby warranting larger and more definitive investigation. This device may be particularly useful for patients with phimosis, which may limit use of conventional techniques due to increased risk for complications and secondary phimosis [6]. The disposable circumcision device provided by the Jiangxi-Yuansheng-Langhe Medical Instrument Co., Ltd., type No. 26, is safe and effective for use in adults over 17 years of age with average adult penis sizes, providing outcomes comparable or superior to CDT treatment. Currently, use for MC in children and adults with abnormal penis sizes (other than 22–28 mm in diameter) is not recommended, although similar principles may be applied to construct models of different sizes in the future.

Conflict of interest

The authors declare no conflict of interest.