

# The CircCurer™ Circumcision Suture Device

C. Roberts, A. Shugaba, M. Liew  
Wrightington, Wigan and Leigh NHS Foundation Trust

## Introduction

We report our initial experience of the CircCurer™ disposable circumcision suture device. It is circular cutter with stapled anastomosis for circumcision (CCSAC). The device was designed based on the principles of an anastomotic bowel stapler.


The proposed benefits of CircCurer™ device-assisted circumcision are:

- Surgical standardisation
- Shorter operating time
- No need for traditional sutures
- Automatic dropping of staples without need for removal
- Good cosmetic outcome

To our knowledge, this is the first reported UK case series.

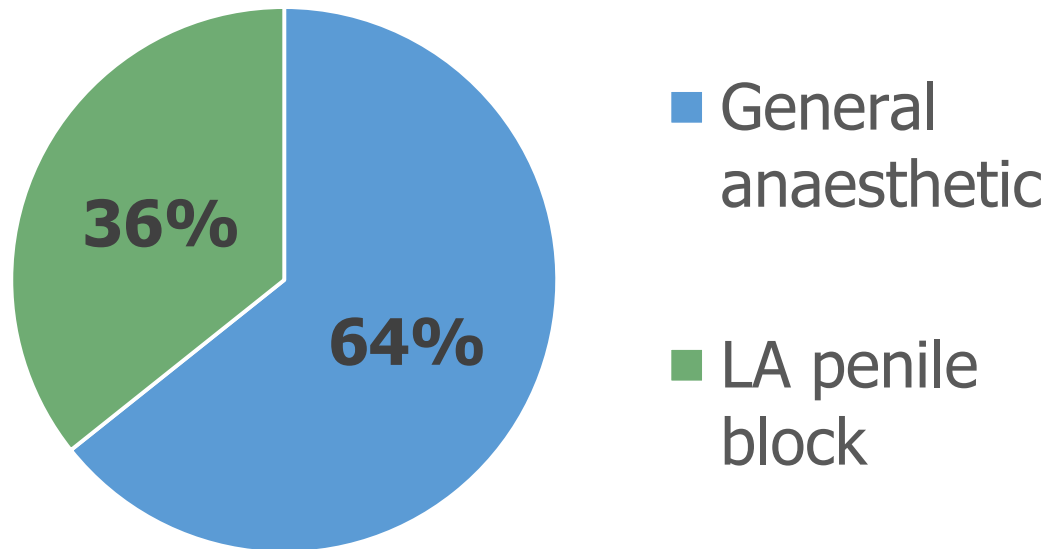
## Patients

14 Patients underwent CircCurer™ device circumcision between April and November 2019.



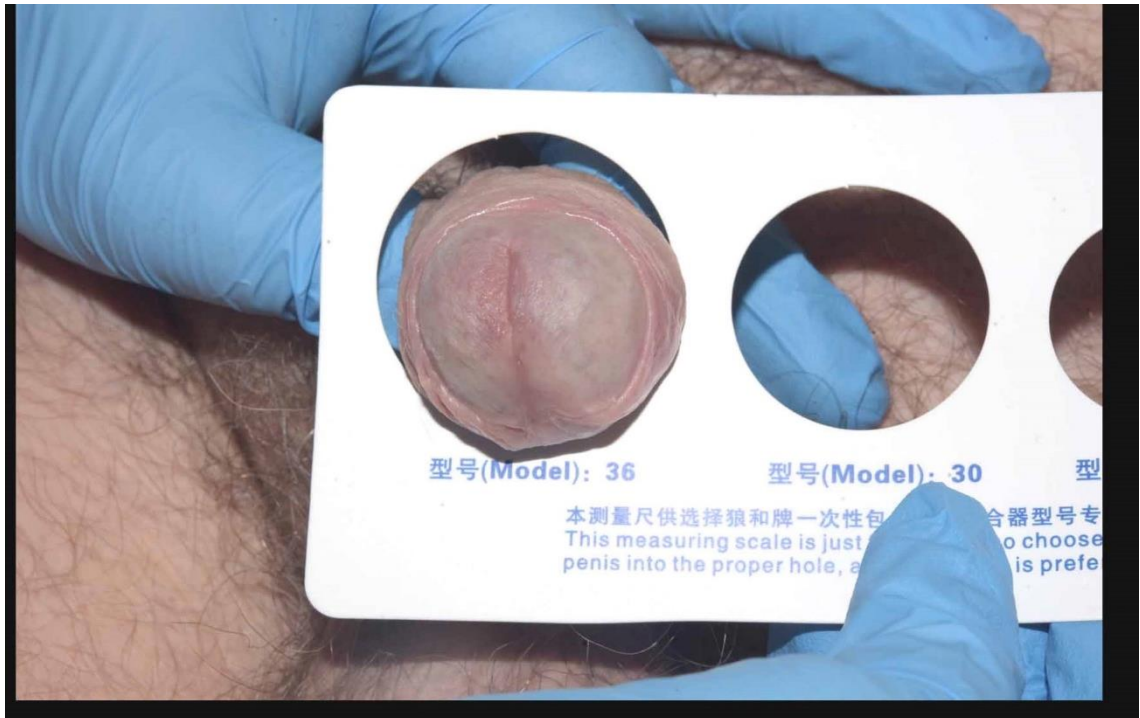n = 14  
Mean age 47y  
[19 – 82]

Chart 1: Type of anaesthesia used



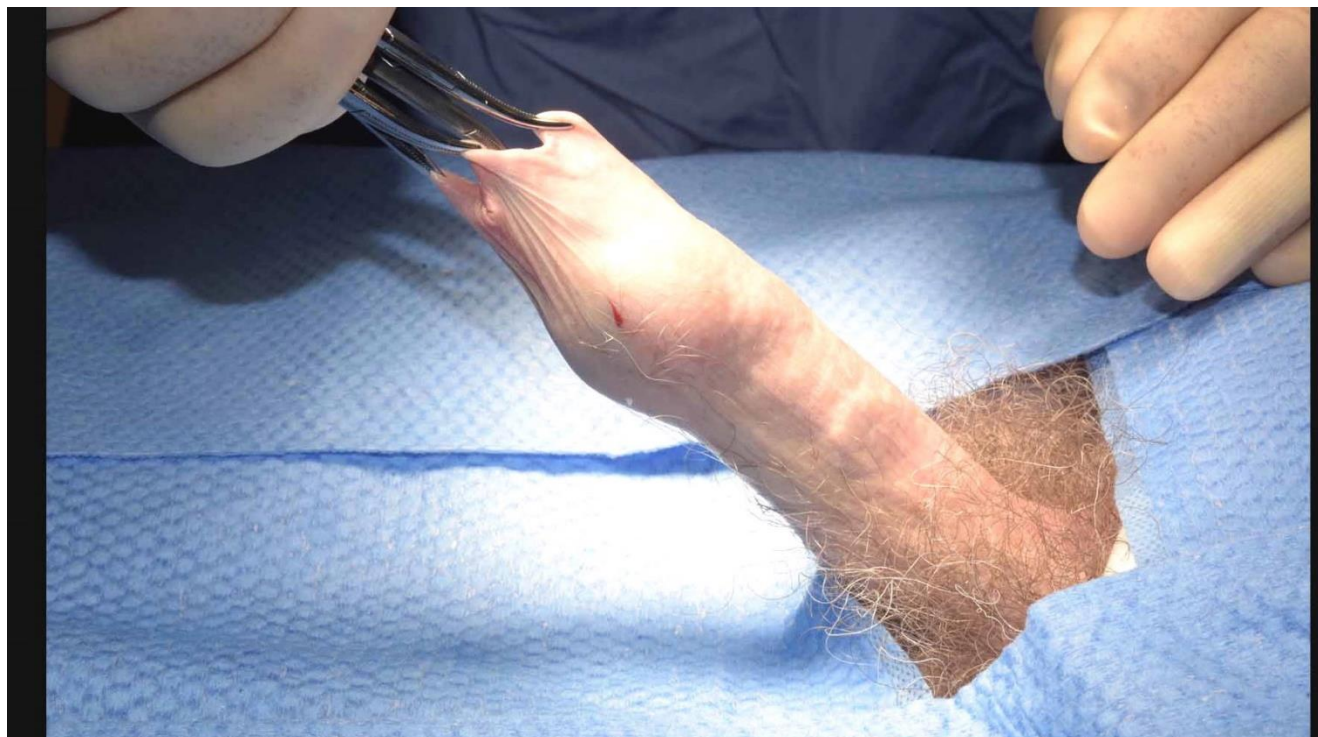## Methods – Operative Steps

The images below detail the key operative steps in CircCurer™ device circumcision. Medical photography was performed with patient permission.



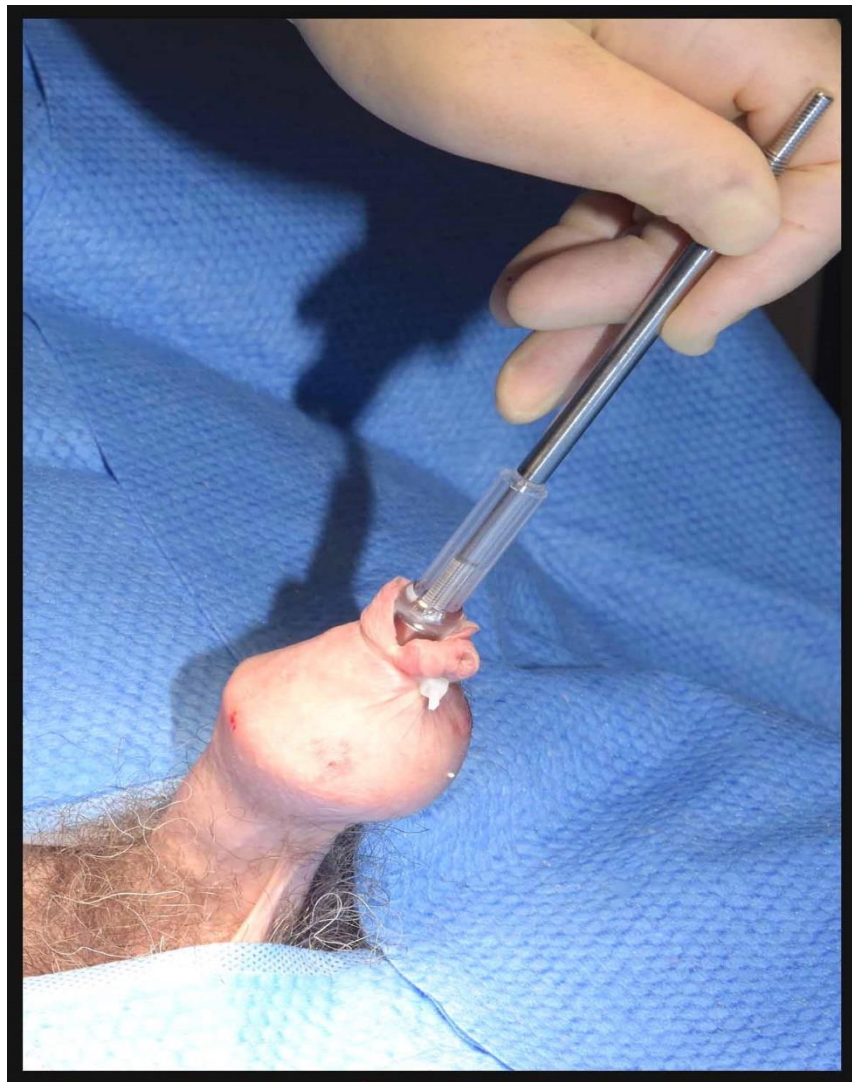
### Step 1: Pre-operative sizing

Several sizes of device available. Sizing performed to ensure correct device used.



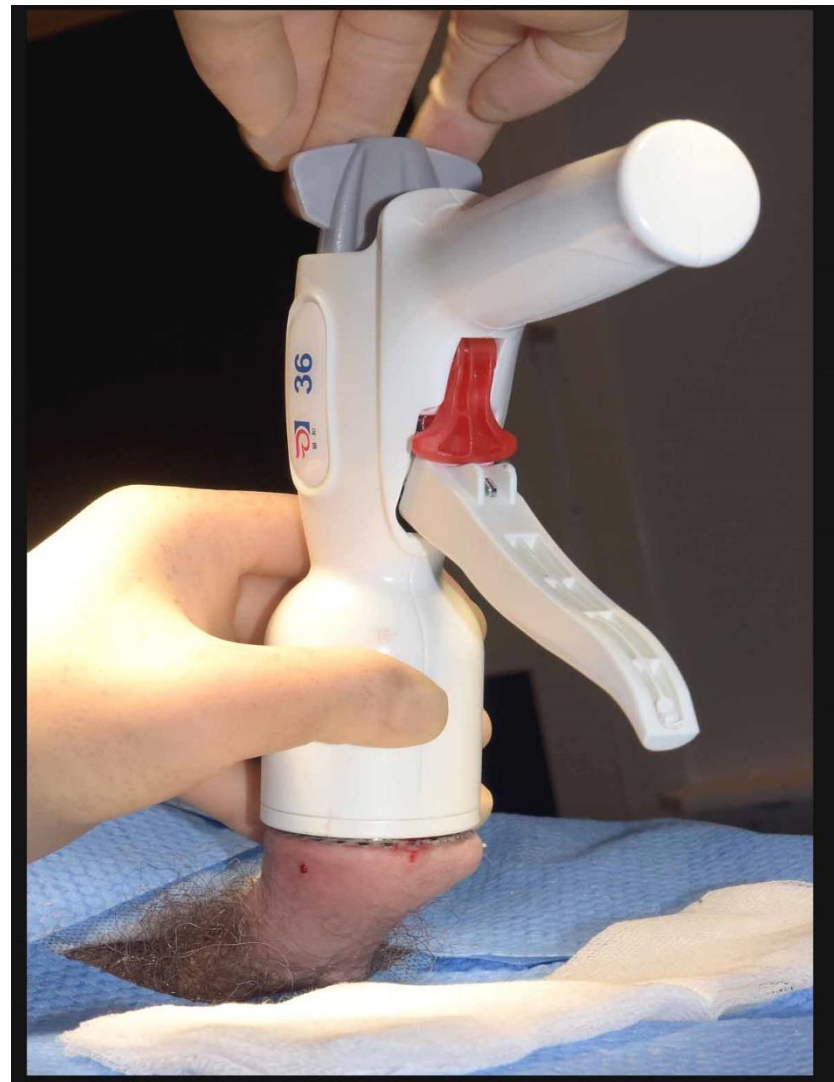
### Step 2: Insertion of glans bell

Artery forceps used to grip prepuce and aid insertion of glans bell and stem. Dorsal slit may be required at this stage if degree of phimosis prevents insertion.



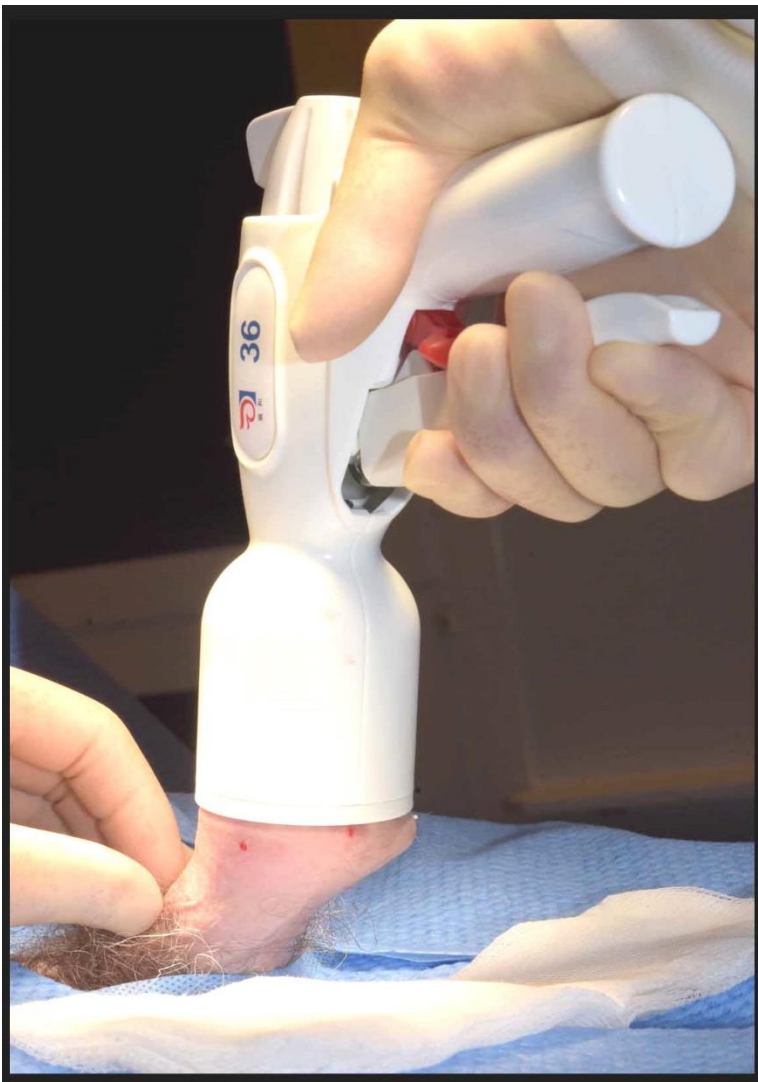### Step 3: Glans bell secured

Glans bell secured to ensure prepuce does not slip from within device



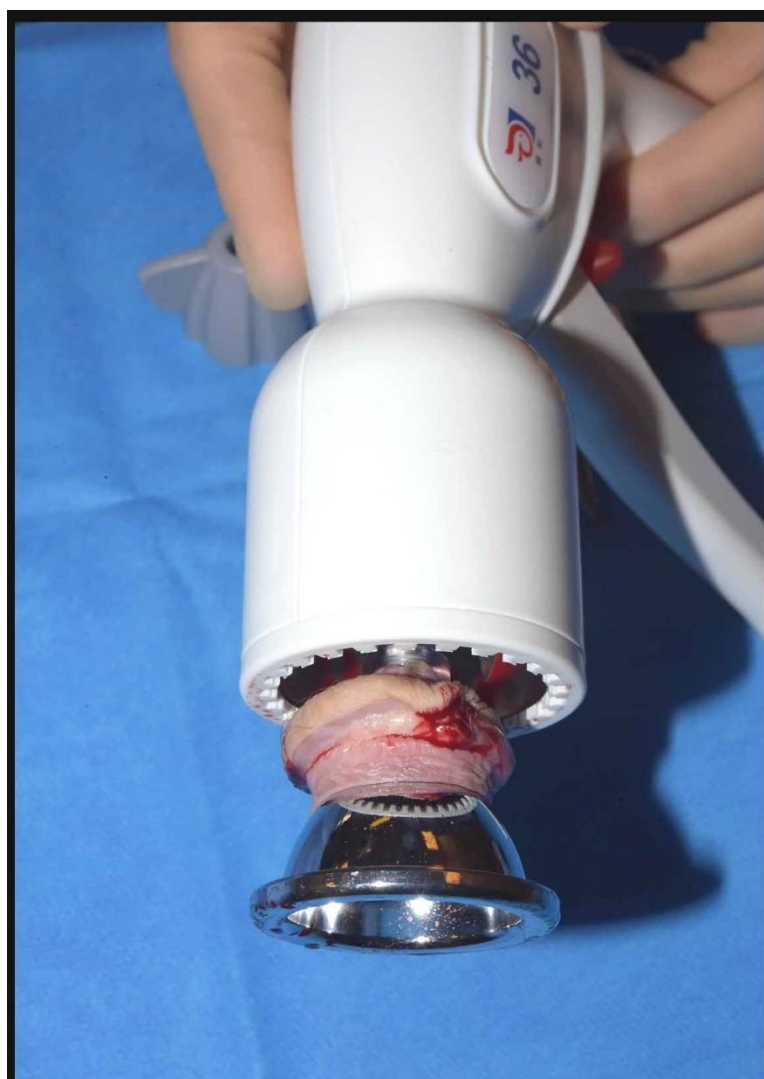### Step 4: Glans bell attached to device

Rod of glans bell inserted into circumcision device and secured



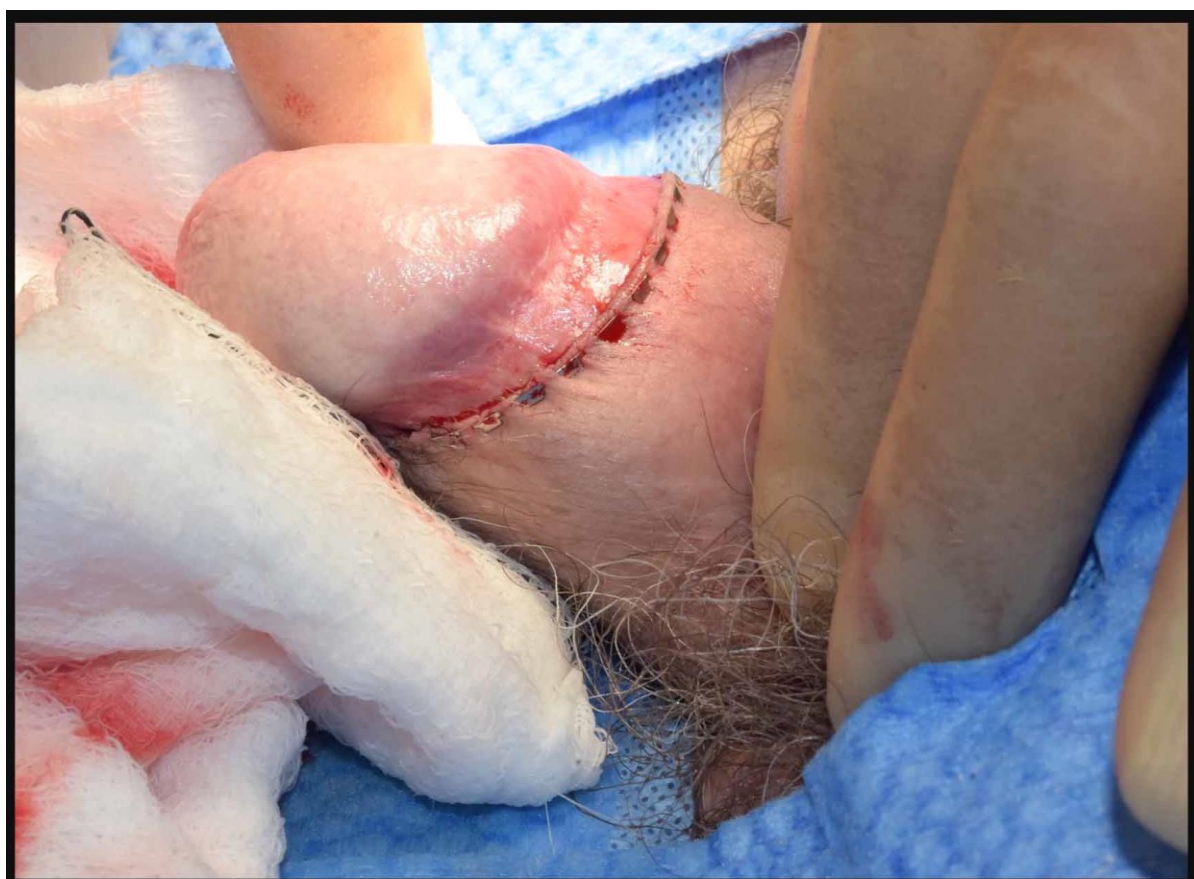### Step 5: Device fired

Concomitant cutting and creation of a stapled anastomosis



### Step 6: Device released

Glans bell released from device. Excised ring of tissue between glans bell and cutting ring.



### Step 7: Compression and wound review

Immediate postoperative appearance of stapled anastomosis.

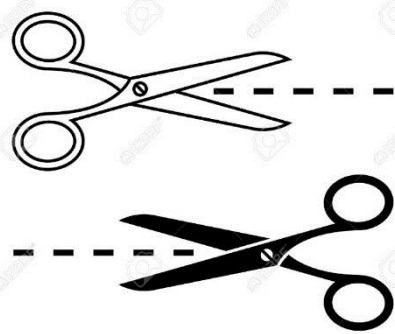
## Results



Median operative time= 11 minutes

Mean operative time = 12 minutes  
[Range 8 – 25 minutes]

### Intraoperative Complications



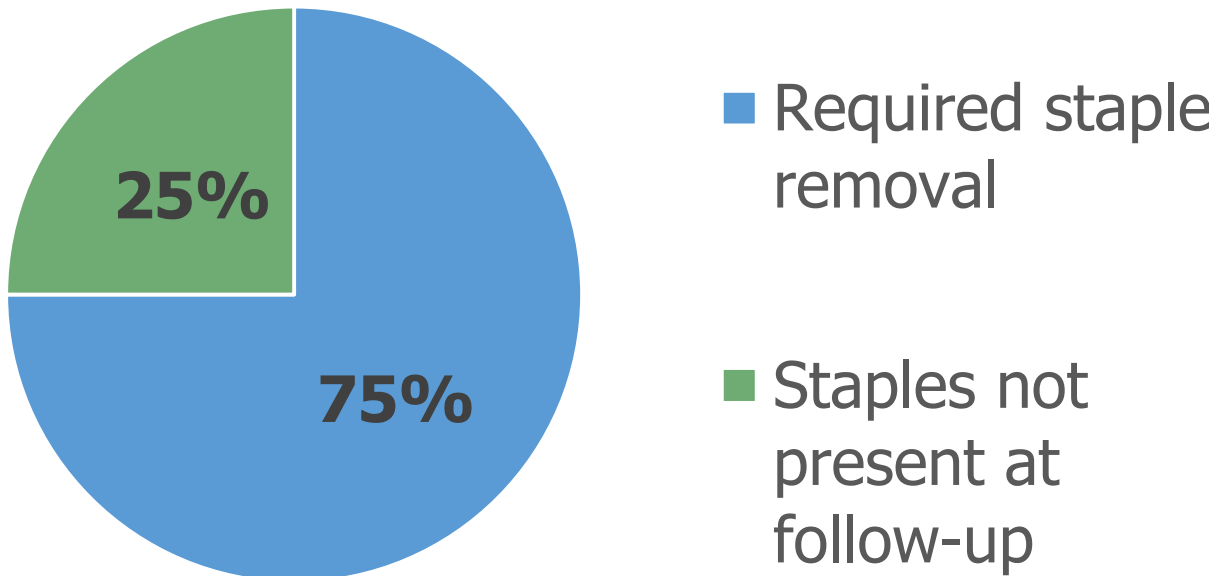
- One case (7%) incomplete detachment of prepuce
- 4 cases (28%) required additional sutures.
- Mean number of sutures required = 5 [ range 1 – 14]

Patients attended for follow-up 6 weeks postoperatively. Wound assessment was undertaken and any remaining staples were removed. Patients were asked to complete a questionnaire regarding their experience. One patient (7%) failed to attend scheduled follow up appointments.

### Post-operative Complications

- 2 (14%) patients developed haematomas. One returned for theatre for evacuation, the other was managed conservatively.
- 3 patients (21%) developed wound infections, treated successfully with oral antibiotics.

Chart 2: Retention of staples

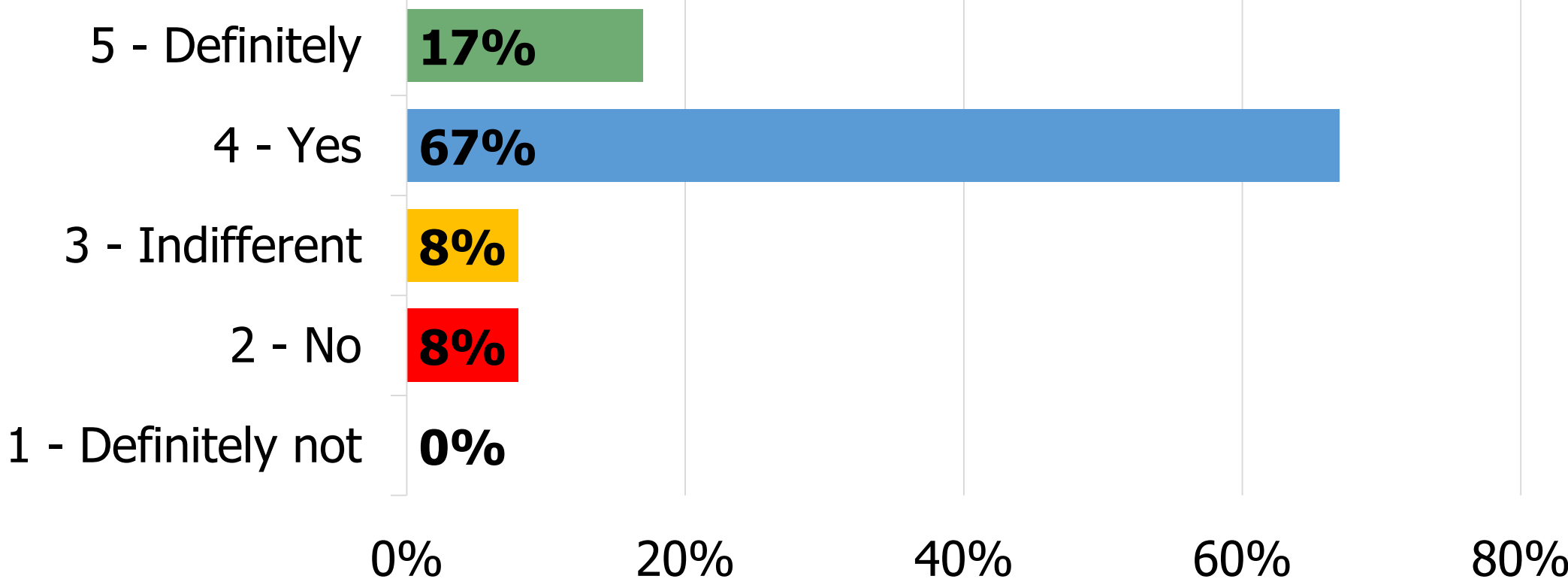


CircCurer™ staples removed manually

### Patient Feedback

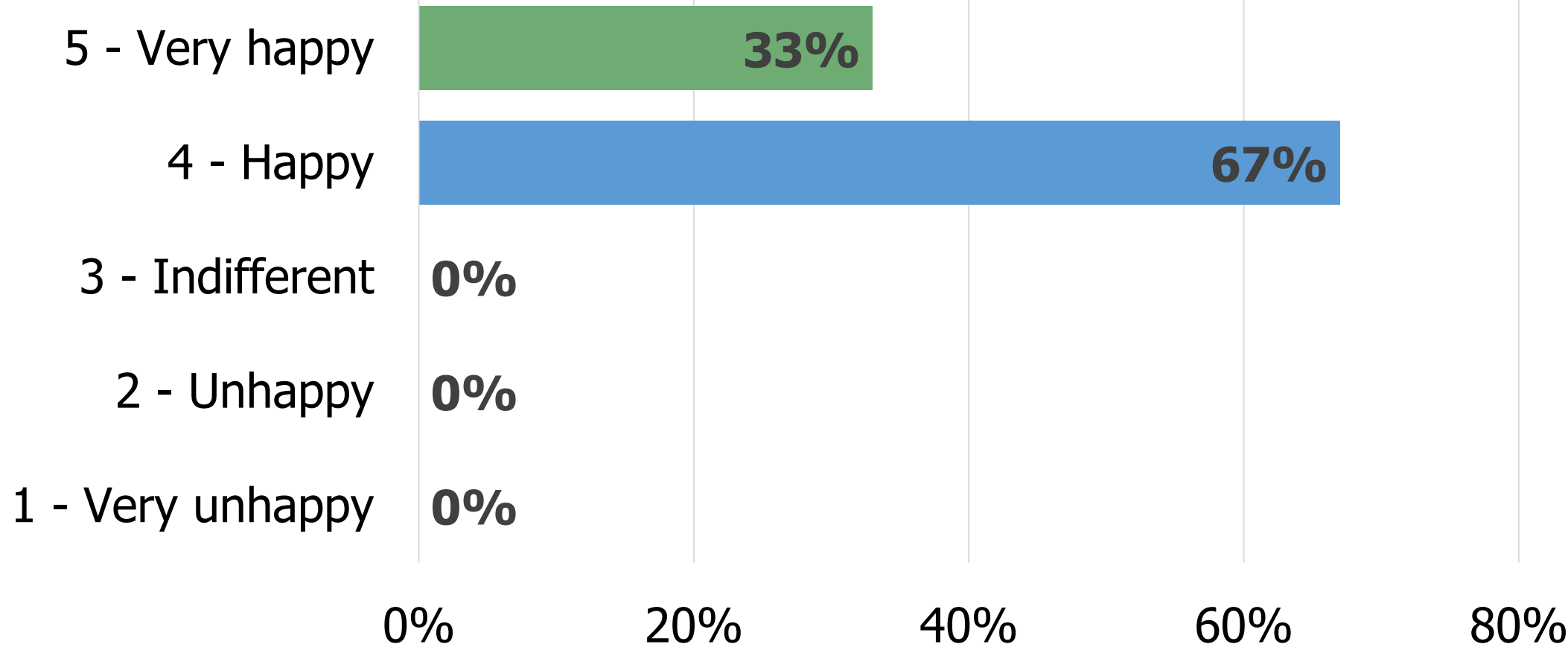
"Would you recommend the CircCurer™ procedure to others?"

Chart 3: "Would you recommend the procedure to others?"



"How happy are you with the cosmetic outcome of your surgery?"

Chart 4: "How happy are you with the cosmetic outcome of your surgery?"



## Discussion

We have seen promising outcomes from our initial experience using the CircCurer™ device. The procedure is well tolerated under local anaesthetic block and has a short operative time.

There have been issues with retention of staples requiring manual removal. However, we have modified our preoperative counselling process and patient information to address this. We have observed an improvement since this change.

The cosmetic results are excellent with 100% of patients of patients reporting that they were either 'happy' or 'very happy' with the outcome of their procedure. 84% of patients would recommend or strongly recommend the technique.

Our operative numbers to date are relatively small, however, our experience has been positive. Circumcision using the CircCurer™ device has the potential to be a high-throughput technique which we intend to investigate further.